

STEM CELLS IN THE REGENERATIVE MANAGEMENT OF INTRA-BONY DEFECTS: A CLINICAL STUDY

Rohit Rai¹, Ranjana Mohan², D. Arunagiri³, Vandana Sharma⁴, Zoya Chowdhary⁵

1. Assistant Professor, Department of Periodontology, Dental College & Hospital, Azamgarh

2. Professor and Head, Department of Periodontology, Teerthanker Mahaveer Dental College & Research Centre, Moradabad

3. Professor & Director Academics & Administration, Department Of Conservative And Endodontics, Dental College & Hospital, Azamgarh

4. Assistant Professor, Department of Periodontology, Vyas Dental College & Hospital, Jodhpur.

5. Post Graduate Student, Teerthanker Mahaveer Dental College & Research Centre, Moradabad.

ABSTRACT

Background: Dental pulp stem cells hold great potential for regeneration in clinical applications due to their accessibility and biologic features. The present study was carried out to evaluate the clinical and radiographic effectiveness of autologous DPSCs in the treatment of intrabony defects in patients with chronic periodontitis.

Materials and methods: Forty healthy patients displaying at least one prevalently 1- or 2-wall intrabony defect and one vital third molar requiring extraction were included in the study. Before carrying out any surgery, patients were enrolled in a strict preparatory periodontal program comprising oral hygiene instructions and scaling and root planning procedures. The third molar was extracted and used as the autologous DPSC source. The dental pulp was mechanically detached and filtered through 50-µm pores to obtain a cellular suspension enriched in stem cells. The selected intrabony defects, one per patient, were filled with the cellular suspension endorsed onto a collagen sponge.

Results: The mean probing depth showed significant reduction from 8.0 – 0.8 mm at baseline to 3.3 – 1.0 mm at the 12-month evaluation. The mean clinical attachment level amounted to 11.0 – 0.8 mm before the surgery and to 6.0 – 1.4 mm at 12 months. At the end of the observational period, the mean radiographic defect fill was 4.2 – 1.9 mm.

Conclusion: Within the confines of this study design, autologous DPSCs proved to represent a very promising tool for the treatment of angular bone defects.

Key Words: stem cells; dental pulp; guided tissue regeneration.

novel regenerative techniques using autologous mesenchymal stem cells.¹

INTRODUCTION

At the present time, researchers are seeking to identify newer ways to improve regenerative therapy's predictability. In this context, the use of tissue engineering has contributed to the growing interest in

Dental pulp has neural crest-derived stem cells. Human dental pulp stem cells (DPSCs) have been isolated and characterized as a population of multipotent stem cells capable of differentiating in vitro into dental pulp-

like structures, osteoblasts, and endotheliocytes.² They have a long lifespan, can be safely cryopreserved, and show the ability to interact with biomaterials.³

Animal studies have provided histologic evidence for the capacity of DPSCs to regenerate both lamellar bone and periodontal tissues in terms of formation of new root cementum, alveolar bone, and periodontal ligament (PDL).⁴

The clinical, histologic, and immunohistochemical efficacy of a novel method for the collection of DPSCs has been demonstrated.^{5,6} The cellular suspension included dental pulp cells with a significant amount of mesenchymal stem/progenitor cells.⁶

The presence of a biologic validation and preclinical animal studies may justify the application of DPSCs in periodontal tissue regeneration. The current study investigates the clinical and radiographic effectiveness of autologous DPSCs on absorbable collagen sponge scaffold in the surgical treatment of intra-bony defects in patients with chronic periodontitis (CP).

MATERIALS AND METHODS

Forty non-smoking patients with CP (23 males and 17 females, aged 40 to 67 years; mean age: 58.5 – 7.5 years) undergoing periodontal therapy in the Department of Periodontology, TMDCRC were consecutively enrolled in the study.

All patients were systemically healthy and presented at least one predominantly 1- or 2-wall intra-bony defect with at least 2 mm of buccal keratinized tissue and one vital third molar requiring extraction for impaction or mal-positioning. The patients were finally selected only after they

reached a full-mouth plaque score and a full-mouth bleeding score <10% at the end of the non-surgical periodontal phase.

The research protocol was approved by the Institutional Ethical Committee of TMU. Written informed consent was obtained from each patient.

Clinical and radiographic parameters were recorded at base- line (before surgery) and 6 and 12 months postoperatively by a single calibrated examiner (RR). Clinical measurements were assessed using a standardized periodontal probe with 1-mm marking and rounded up to the nearest millimeter. Assessments included plaque accumulation, bleeding on probing, probing depth (PD), gingival recession (gingival margin–cemento-enamel junction [GM-CEJ]), and clinical attachment level (CAL). Individually customized bite blocks and parallel angle technique were used to obtain standardized radiographs. The anatomic landmarks were identified as described by Schei et al.⁸ The radiographic angle (RA) and the linear distance from the bone crest to the base of the defect (BC-BD; intra-bony defect depth) were recorded by means of image analysis software.⁹ The difference between BC-BD recorded at baseline and the 1-year examination was identified as the amount of bone fill within the intra-bony defect.

All surgeries were performed by using an operative microscope. For the access flap, modified or simplified papilla preservation technique^{10, 11} was selected on the basis of the width of the interdental papilla. The elevation of the flap was kept at a minimum to allow the exposure of the defect and the careful debridement of the root surface.

The third molar was extracted and washed in 0.2% chlorhexidine for 90 seconds. The crown was separated from the roots along the CEJ. The pulp tissue was gently collected under sterile conditions and mechanically dissociated.⁵ Subsequently, it was passed through disposable 50-mm filters in 2 mL sterile physiologic solution to obtain a cellular suspension enriched in progenitor stem cells.^{5,6} The cellular suspension was endorsed on to a collagen sponge scaffold and used as a collagen graft. This technique has the advantage of not requiring any cellular manipulation. The enriched collagen sponge was gently placed to completely fill the intra-bony defect. Flaps were sutured with interrupted crisscross horizontal mattress sutures.

Patients were prescribed 500 mg amoxicillin plus 125 mg clavulanic acid twice daily for 7 days and instructed to refrain from mechanical oral hygiene for the first 2 weeks. Sub-gingival instrumentation was not performed in the treated areas for 12 months.

RESULTS

As reported in Table 1, the application of the DPSCs/ collagen sponge resulted in an average CAL gain of 5.0 – 1.2 mm associated with a residual mean PD of 3.3 – 1.0 mm and a remarkable stability of the GM at 1 year. No sites lost attachment, and all sites gained 4 mm. The radiographic analysis of 1-year show mean bone fills of 4.2 – 1.9 mm. The periapical radiographs showed the complete closure of all defects by bone-like tissue. The result is statically significant.(Graph 1-4)

DISCUSSION

The clinical and radiographic findings seem to demonstrate the efficacy of autologous DPSCs and collagen sponge in the treatment of deep intra-bony defects. At 1 year, the mean CAL gain amounted to 5.0 – 1.2 mm and was associated with a stability of the GM. Radiographically, all defects were filled with bone-like dense tissue.¹² Because no histologic assessment was performed, no definitive statement can be made concerning the tissue properties achieved.¹³ However, the unfavorable defect morphology and the application of a radiolucent, non-supportive biomaterial with a rapid resorption rate in combination with the outcomes described previously led the present authors to hypothesize that periodontal regeneration occurred.

The efficacy of a mechanical and dimension-based method for DPSC collection has been demonstrated.^{5,6} After mechanical dissociation, dental pulp cells were filtered through a 50-mm strainer. Under this dimension the percentage of cells expressing stem antigens grows dramatically, avoiding a magnetic or flow cytometric sorting.¹⁴ The obtained cellular suspension included a percentage of CD34⁺ stem cells amounting to 74%.⁶

The same protocol has been used in the present investigation to obtain a cellular suspension enriched in pulp stem cells to load on a biologically inert scaffold. A collagen III sponge was selected for its biologic properties. Collagen is the main protein of undifferentiated mesenchymal tissue, and it is inactive in terms of periodontal regeneration. The loading of cellular suspension on a collagen sponge is important to support stem cells along with the first weeks of differentiation.¹⁵

CONCLUSION

Therefore, within the confines of the present study, it can be concluded that autologous DPSCs may represent a very

promising tool for the treatment of angular bone defects with disparaging architecture.

REFERENCES

1. Peng L, Ye L, Zhou XD. Mesenchymal stem cells and tooth engineering. *Int J Oral Sci* 2009;1:6-12.
2. Huang GT, Gronthos S, Shi S. Mesenchymal stem cells derived from dental tissues vs. those from other sources: Their biology and role in regenerative medicine. *J Dent Res* 2009;88:792-806.
3. Graziano A, d'Aquino R, Laino G, Papaccio G. Dental pulp stem cells: A promising tool for bone regeneration. *Stem Cell Rev* 2008;4:21-26.
4. Khorsand A, Eslaminejad MB, Arabsolghar M, et al. Autologous dental pulp stem cells in regeneration of defect created in canine periodontal tissue. *J Oral Implantol* 2013;39:433-443.
5. Graziano A, D'Aquino R, Brunelli G, Fanali S, Carinci F. Sinus lift augmentation using pulp stem cells: A case report and histological evaluation. *Eur J Inflammation* 2011;9(Suppl. 1):89-94.
6. d'Aquino R, De Rosa A, Lanza V, et al. Human mandible bone defect repair by the grafting of dental pulp stem/progenitor cells and collagen sponge biocomplexes. *Eur Cell Mater* 2009;18:75-83.
7. Armitage GC. Development of a classification system for periodontal diseases and conditions. *Ann Periodontol* 1999;4:1-6.
8. Schei O, Waerhaug J, Lovdal A, Arno A. Alveolar bone loss as related to oral hygiene and age. *J Periodontol* 1959;30:7-16.
9. Aimetti M, Romano F, Pigella E, Pranzini F, Debernardi C. Treatment of wide, shallow, and predominantly 1-wall intrabony defects with a bioabsorbable membrane: A randomized controlled clinical trial. *J Periodontol* 2005;76:1354-1361.
10. Cortellini P, Prato GP, Tonetti MS. The modified papilla preservation technique. A new surgical approach for interproximal regenerative procedures. *J Periodontol* 1995;66:261-266.
11. Cortellini P, Prato GP, Tonetti MS. The simplified papilla preservation flap. A novel surgical approach for the management of soft tissues in regenerative procedures. *Int J Periodontics Restorative Dent* 1999;19:589-599.
12. Cortellini P, Pini Prato GP, Tonetti MS. Periodontal regeneration of human infrabony defects. II. Re-entry procedures and bone measures. *J Periodontol* 1993;64:261-268.
13. Caton J, Zander HA. Osseous repair of an infrabony pocket without new attachment of

connective tissue. J Clin Periodontol 1976;3:54-58.

14. d'Aquino R, Graziano A, SampaolesiM, et al. Human postnatal dental pulp cells co-differentiate into osteoblasts and endotheliocytes:A pivotal synergy leading to adult bone tissue

formation. Cell Death Differ 2007;14:1162-1171.

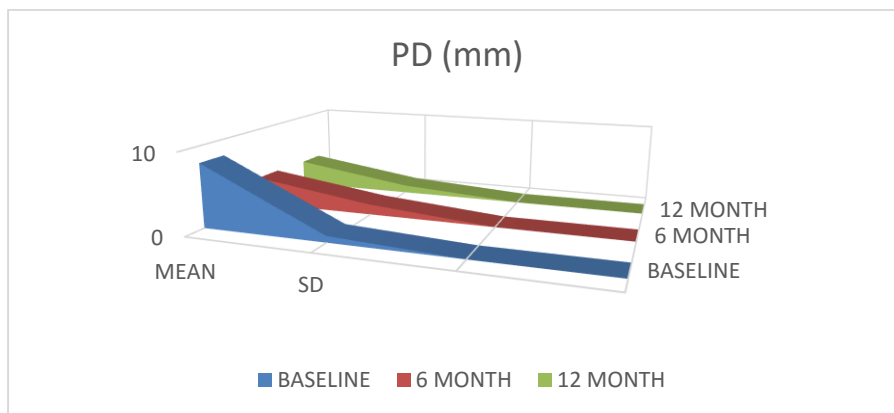
15. Sumita Y, HondaMJ, Ohara T, et al. Performance of collagen sponge as a 3-D scaffold for tooth-tissue engineering. Biomaterials 2006;27:3238-3248.

TABLE:

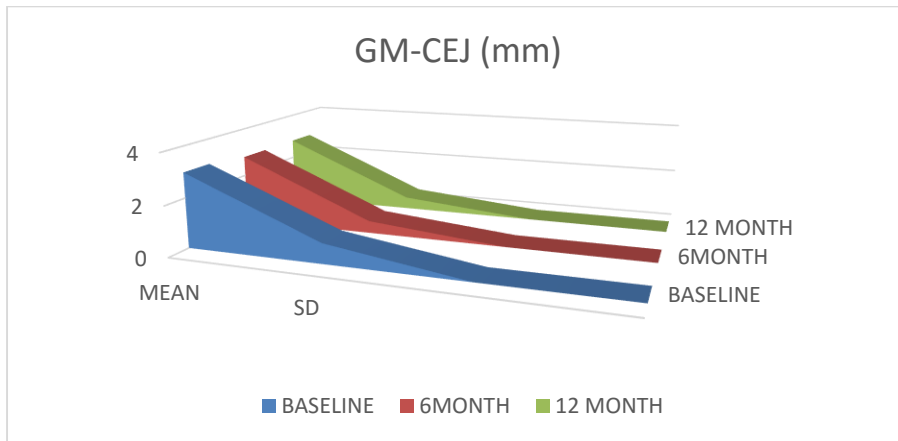
	Baseline					6 Months				12 Months			
	PD (mm)	GM-CEJ (mm)	CAL (mm)	BC-BD (mm)	RA (°)	PD (mm)	GM-CEJ (mm)	CAL (mm)	BC-BD (mm)	PD (mm)	GM-CEJ (mm)	CAL (mm)	BC-BD (mm)
Mean	8.0	3.0	11.0	5.6	33.8	3.5	2.8	6.3	2.2	3.3	2.8	6.0	1.4
SD	0.8	0.8	0.8	1.8	6.9	1.3	0.5	1.7	0.2	1.0	0.5	1.4	0.2

TABLE 1: Clinical and Radiographic Parameters

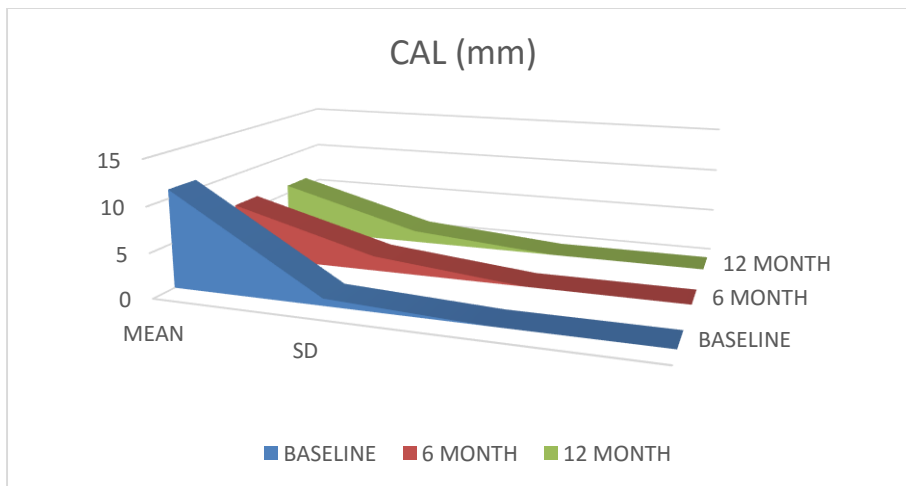
GRAPHS:



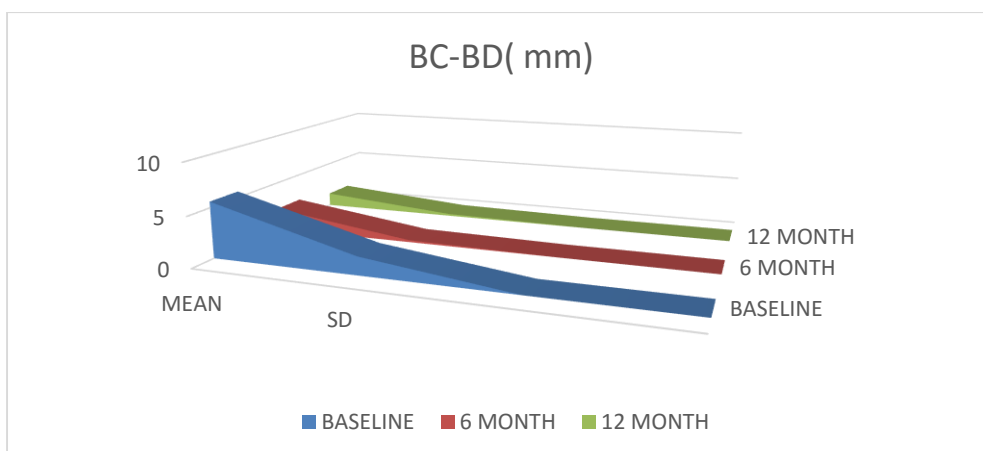
Graph 1: Showing change into Mean and SD value of PD (mm)



Graph 2: Showing change into Mean and SD value of GM-CEJ (mm)



Graph 3: Showing change into Mean and SD value of CAL (mm)



Graph 4: Showing change into Mean and SD value of BC-BD (mm)