

PROSTHODONTIC MANAGEMENT OF OBSTRUCTIVE SLEEP APNEA WITH RETROPALATAL ZONE OF CONSTRICTION BY MEANS OF NASO-PHARYNGEAL APPLIANCE

Samir Alam¹, Pankaj Kumar Singh², Gautam Bagchi³, Vipin Bhatnagar⁴, Anuj Garg⁵, Alka Singh⁶

1.Post Graduate Student, Department of Prosthodontics and Crown & Bridge, Dental College Azamgarh, Uttar Pradesh, India

2.Reader, Department of Prosthodontics and Crown & Bridge, Dental College Azamgarh, Uttar Pradesh, India

3.Professor, Department of Prosthodontics and Crown & Bridge, Dental College Azamgarh, Uttar Pradesh, India

4.Professor and Head, Department of Prosthodontics and Crown & Bridge, Dental College Azamgarh, Uttar Pradesh, India

5.Professor and Head, Department of Oral Pathology, Dental College Azamgarh, Uttar Pradesh, India

6.Research Scientist, Department of Orthopaedics KGMU, Lucknow.

ABSTRACT

This research aimed to broaden the scope of managing obstructive sleep apnea (OSA) by developing a novel appliance tailored for individuals with mild OSA exhibiting retropalatal zone constriction. Existing oral appliance modalities primarily target the retroglossal zone, neglecting the potentially more prevalent retropalatal narrowing observed in OSA. The study conducted a thorough investigation using three-dimensional imaging analysis to understand the dynamic changes in upper airway (UA) constriction during sleep, particularly in mild OSA subjects compared to healthy individuals.

The first phase of the research highlighted four key findings:

1. Diagnosis of OSA should consider the zone of UA narrowing rather than symptom severity alone.
2. OSA subjects can be categorized into retropalatal and retroglossal narrowing types.
3. Retropalatal narrowing is more prevalent, especially in mild OSA.
4. Different treatment approaches are required for each type of narrowing.

Additionally, the first phase established a reliable technique for three-dimensional imaging analysis of UA, essential for subsequent research phases. Building on these findings, the second phase focused on developing a new appliance design specifically for managing mild OSA with retropalatal narrowing. Preliminary evaluation demonstrated promising efficacy through subjective and objective analyses.

The third phase aimed to definitively evaluate the efficacy of the newly developed Naso-pharyngeal appliance (NPA) in managing mild OSA with retropalatal zone narrowing. This evaluation involved comprehensive three-dimensional image analysis of UA dimensions before and after NPA use. Statistical analysis revealed significant improvements in UA dimensions, including airway patency, antero-posterior width, lateral width, surface area, and volume during sleep with the NPA.

In conclusion, the research presents a paradigm shift in OSA management by emphasizing personalized treatment based on UA narrowing zones and introducing a novel appliance design targeted at retropalatal constriction. The findings underscore the potential of the NPA to significantly improve sleep apnea symptoms in affected individuals.

Keywords: Obstructive Sleep apnea, NPA, CPAP, Cephalometrics.

INTRODUCTION:

Obstructive sleep apnea (OSA) is a prevalent condition affecting approximately one in every five individuals, with varying degrees of severity ¹. Its etiology is multifactorial, stemming from congenital and degenerative upper airway diseases, as well as certain behavioral and systemic conditions, making diagnosis and management challenging.

OSA exhibits a high incidence rate, affecting around 25% of males and 16% of females ¹. Notably, it can occur across all age groups, from infancy to old age, impacting multiple physiological systems including respiratory, cardiac, circulatory, endocrine, and nervous systems. Additionally, OSA contributes to psychological disturbances such as mental fatigue, lack of concentration, and an increased risk of accidents.

Given its widespread prevalence and systemic effects, urgent attention from the scientific community is warranted ². Initial management typically involves behavioral and lifestyle modifications such as weight loss, altering sleep positions, and avoiding alcohol and sedatives ³. However, these approaches may not yield immediate benefits.

Medical management involves investigating and ruling out central causes of sleep apnea, followed by the consideration of obstructive sleep apnea. While continuous positive airway pressure (CPAP) is an effective option for stenting the upper airway, its long-term compliance can be challenging for some patients, necessitating alternative treatments.

Surgical interventions may be pursued when conservative measures fail, including nasal airway restoration, adenoidectomy, tonsillectomy, and reduction of tongue volume. Advanced surgical techniques such as mandibular advancement and uvulo-palato-pharyngeoplasty are also available for refractory cases.

However, not all patients are suitable candidates for surgery, and many may prefer non-invasive options. Dental surgeons play a crucial role in providing non-surgical interventions like tongue retaining devices, which require careful design and patient selection to ensure efficacy and patient comfort.

This article endeavors to pioneer the development and assessment of innovative oral appliance modalities meticulously designed to address the specific needs of individuals with mild obstructive sleep apnea (OSA) characterized by retropalatal zone constriction. By meticulously

tailoring these oral appliances to target the retropalatal zone of UA obstruction during sleep, our research aims to offer efficacious and patient-friendly alternatives to conventional management approaches. Through this endeavor, the overarching objective is to introduce a novel oral appliance modality that not only mitigates the limitations of existing devices but also significantly enhances the management of OSA with retropalatal constriction, ultimately improving patient outcomes and quality of life.

MATERIALS AND METHOD:

This research was conducted across three consecutive phases, each phase building upon the findings of the previous one to refine research questions and objectives further. Focused exclusively on patients with milder forms of obstructive sleep apnea (OSA), this study aimed to address the needs of a majority who might not tolerate CPAP machines or opt for surgical interventions.

Phase I involved a comprehensive 3-dimensional imaging analysis of the upper airway to explore dimensional changes during sleep, comparing healthy individuals with mild OSA subjects. This phase aimed to achieve three objectives: firstly, to delineate UA changes during sleep and identify different levels of

obstruction; secondly, to categorize mild OSA subjects based on these levels of obstruction; and thirdly, to statistically determine the incidence rate of each category of mild OSA based on the level of obstruction. The insights gained from this phase facilitated improved diagnosis and treatment planning, shedding light on the mechanisms of OSA within the 'Cause-Effect-Management' paradigm. Additionally, Phase I established a reliable technique for 3-dimensional imaging analysis of the UA, ensuring precision and reliability in subsequent phases, thereby forming a seamless continuum of research progress. Phase II of the research involved testing a new appliance, named the Naso-Pharyngeal Appliance (NPA), designed specifically to address retro-palatal obstruction in OSA subjects. This phase aimed to refine the appliance design through actual usage in mild OSA subjects with retro-palatal obstruction, utilizing imaging techniques, oral endoscopy, and nasal endoscopy for evaluation. The positive outcomes observed in Phase II led to the progression to Phase III.

Detailed Methodology of Phase I:

Hypothesis: The null hypothesis posited that adults with reduced upper airway dimensions during sleep do not exhibit increased risk of sleep fragmentation, micro-arousals, or reduced sleep efficiency

compared to those without airway reduction.

Design: A case-control study design with independent groups and a double-blind approach was adopted to test the hypothesis and address research questions.

Sample: A total of 80 subjects were recruited, comprising 40 healthy individuals (Control group -Group A) and 40 subjects with mild OSA (Group B) selected via random assignment. Selection criteria included demographic (age, gender, BMI), clinical (body type, daytime sleepiness), and cephalometric variables (SNA, SNB, PAS, PNS-U, Mp-H, anterior facial height).

Selection Criteria: Participants were matched for demographic and cephalometric variables, with strict inclusion criteria for both control and sample groups, ensuring homogeneity within groups and minimizing confounding factors.

In summary, Phase I employed a comprehensive methodology to investigate UA dimensional changes and sleep parameters in healthy individuals and mild OSA subjects, providing valuable insights into the relationship between upper airway obstruction and sleep disturbances.

Phase III focused on a more extensive evaluation of treatment outcomes. A randomized controlled clinical trial with a double-blind design was conducted to assess the efficacy of NPA in improving airway volume and dimensions during sleep in mild OSA subjects with retro-palatal zone constriction.:

Following the initial assessment, subjects assigned to Group B, characterized by mild obstructive sleep apnea with retro-glossal zone constriction, underwent treatment with Mandibular Repositioning Splint (MRS) according to the established clinical protocol outlined in Phase II. This involved taking irreversible hydrocolloid impressions of the maxillary and mandibular arches and creating a bite registration with the mandible in a protruded position. Subsequently, the casts were mounted on a semi-adjustable articulator, and the MRS appliance, designed to advance the mandible and prevent tongue fall back in the supine position, was fabricated using clear heat-processed polymethyl methacrylate resin (PMMA). The thickness of the major portion of the appliance, covering and closely adapted to the hard palate, was maintained at an average of 2 mm to minimize bulkiness and discomfort. Additionally, all surfaces of the appliance, especially those facing the tongue, were

smoothed to prevent soft tissue irritation or impairment of speech, swallowing, and other functions.

Subjects assigned to Group C, exhibiting mild obstructive sleep apnea with retro-palatal zone constriction, were treated with the Naso-Pharyngeal Appliance (NPA). Impressions were made with irreversible hydrocolloid extending posteriorly up to the nasopharyngeal aperture, and casts were created accordingly. The NPA, comprising an extension portion with ports engaging the nasopharyngeal apertures to widen the airway, was fabricated using heat-processed PMMA resin after incorporating retentive elements. The extension portion of the appliance, housing the two ports suspended by wires, was meticulously designed to match the measurements of the surface area of the retro-palatal zone of the upper airway obtained from pre-treatment diagnostic evaluations using three-dimensional computed tomography (CT) scans. This customized approach ensured optimal fit and efficacy of the appliance in maintaining airway patency during sleep.

Following appliance placement, subjects wore them for three weeks under close supervision. During this period, subjects were monitored for any adverse effects, and adjustments to the appliances were made as necessary to optimize comfort and efficacy. After the three-week treatment period,

three-dimensional CT scans of the upper airway were conducted using the same methodology as described in Phase I. These scans allowed for the precise assessment of changes in upper airway dimensions, including volume, patency, antero-posterior width, and lateral width at both retro-glossal and retro-palatal zones.

The obtained data were meticulously tabulated and subjected to comprehensive statistical analysis to determine the significance of any observed differences between pre- and post-treatment measurements within each group and across groups. This rigorous approach aimed to provide valuable insights into the efficacy of MRS and NPA in managing mild obstructive sleep apnea with specific emphasis on retro-palatal zone obstruction.

By adhering to this detailed methodology, the study aimed to contribute substantially to the understanding of optimal treatment modalities for mild obstructive sleep apnea, thereby improving patient outcomes and quality of life.

Figure 1: Zones of constriction in OSA.

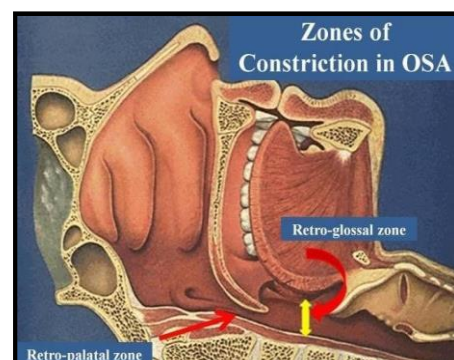


Figure 2: Overnight Diagnostic Polysomnography (ODP) for sleep analysis.



Figure 3: Positioning the subject with cephalostat and cephalometric imaging.

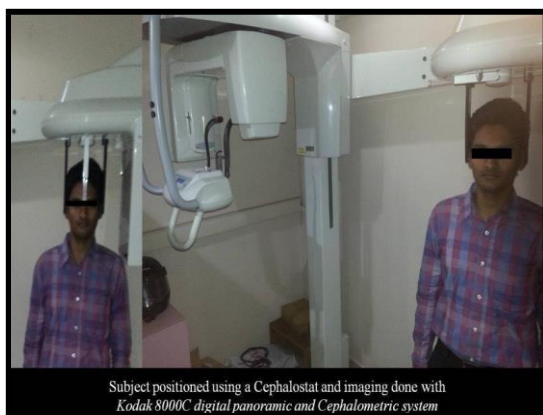

Figure 4: Anatomical markers and measurements for Lateral cephalometric analysis of UA.

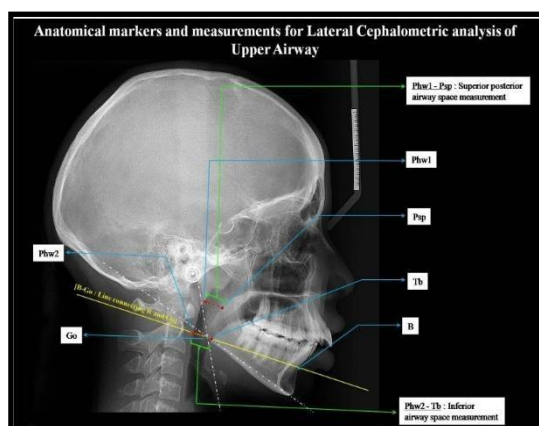


Figure 5: Measurement of UA patency done from CT images by computerized method (Fuji Synapse Vincent software).

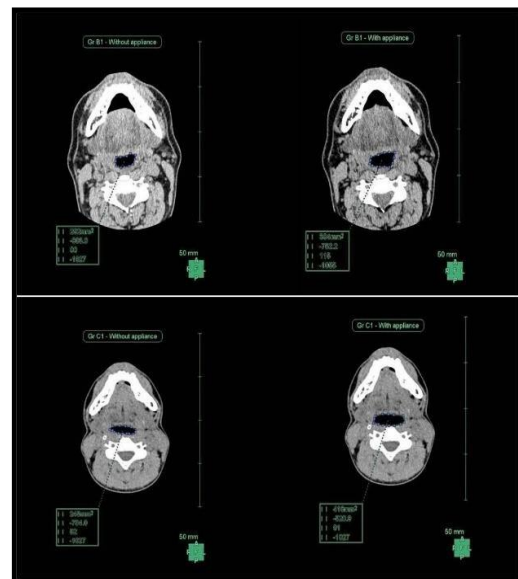


Figure 6: Fragmentation and Processing technique - 3-d imaging of UA - Amira 3.1 software (Mercury Computer Systems 3D Viz group).

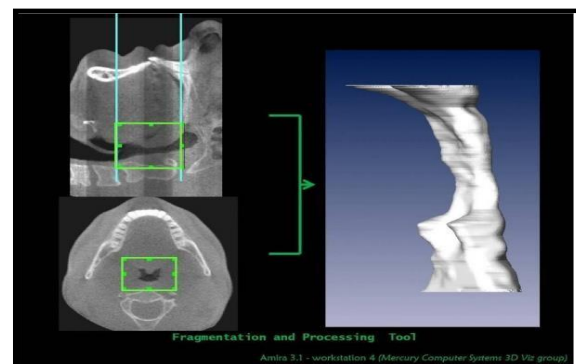


Figure 7: 3-d images of UA developed for dimensional analysis.

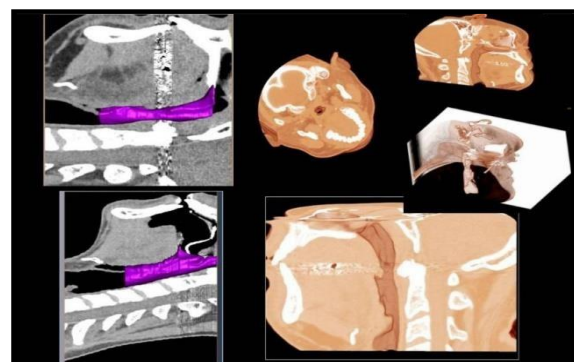


Figure 8: UA 3-d reconstruction by rapid prototyping.



Figure 9: UA 3-d reconstruction physical model,

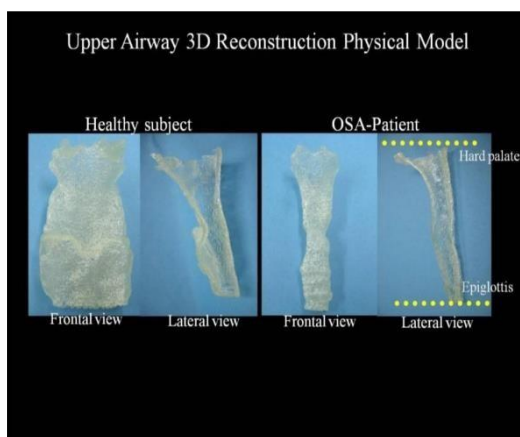


Figure 10: Mandibular repositioning splint (MRS)

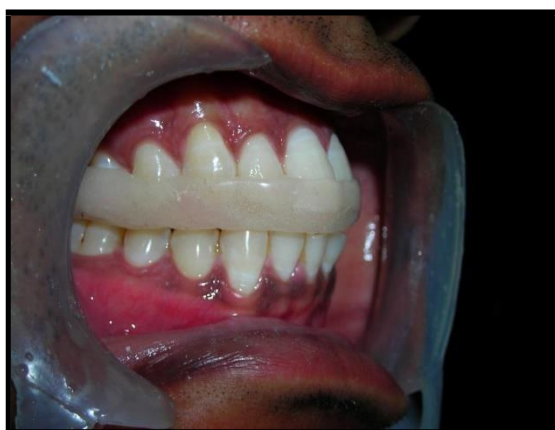

Figure 11: Naso-pharyngeal appliance,

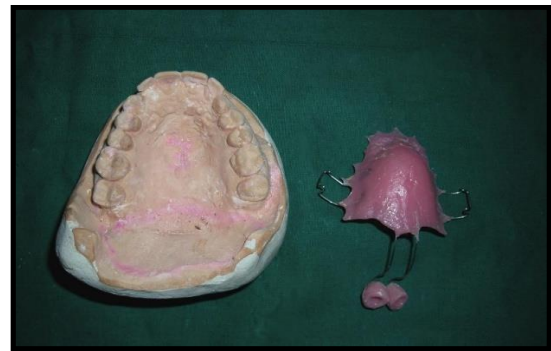

Figure 12: Naso-pharyngeal appliance

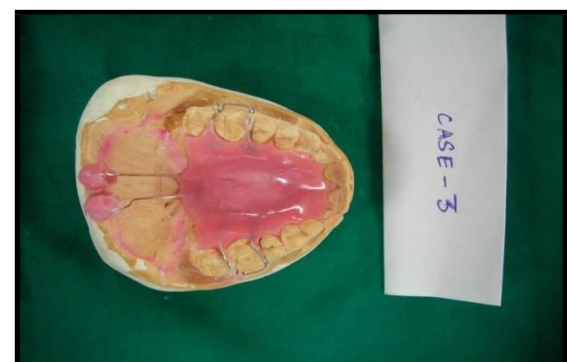

Figure 13: Naso-pharyngeal appliance – mode of action,

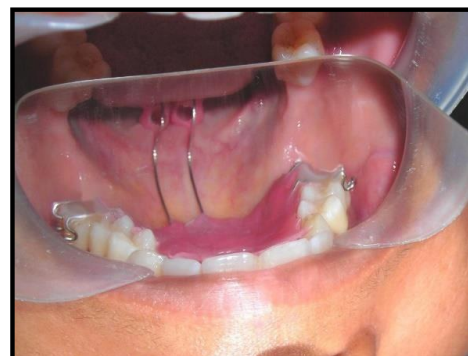
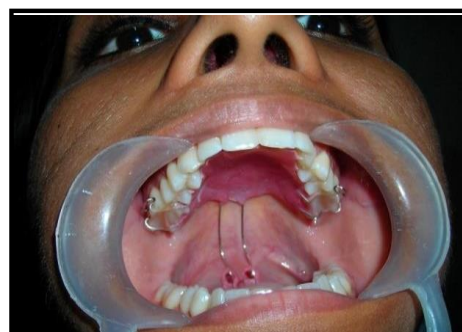
Figure 14: Naso-pharyngeal appliance – mode of action



RESULTS:

In phase I of research, UA dimension measurements were made for all subjects - Group A of healthy individuals and Groups B of subjects with sleep disturbance. The three-dimensional image developed by the Fragmentation and Processing technique enabled visualization of UA and comparison of volume between healthy and mild OSA subjects. The Volume values, Patency values (surface area of UA opening), Anterio-posterior and Lateral widths obtained from different zones of obstruction (Retro-glossal and retro-palatal) were tabulated (Tables 2 and 3) and statistically analyzed for comparison between - healthy and mild OSA subjects and furthermore for evaluating the different zones of obstructions in mild OSA subjects (Graph I & II). In phase III of research, UA patency values for subjects in group A, groups B and C with and without MRS/NPA were noted and statistical analysis done (Table 4). 3-dimensional UA measurements (volume, a-p width, lateral width and area at Retroglossal and Retropalatal regions) were calculated for all three groups with groups B and C before/after MRS/NPA placement (Table 5). Statistical analyses were done to evaluate differences within and between control (group A) to sample groups (B and C) by ANOVA statistical test (Table 6) and

Post-hoc tests (Table 7). Statistical analysis was done between Groups B and C to compare the treatment outcomes of MRS and NPA using ANOVA test (Table 8). The null hypothesis was rejected based on the outcome of the statistical analysis ($p < 0.0001$).

Results revealed that subjects in Group A exhibit significantly higher values of UA patency, volume, area, anterior-posterior and lateral widths at Retroglossal and Retropalatal regions than Group B and C subjects (*Graph III*). Subjects in Group C showed better improvement in the airway dimensions after NPA placement than subjects in group B after MRS placement (*Graph IV*).

DISCUSSION:

Preamble: Upper airway (UA), a dynamic constituent of respiratory system, is mulled over to influence sleep efficiency and architecture by distressing the airflow pattern during sleep, resulting in Respiratory effort related arousals (RERA). UA consists of two components: muscular and collapsible oro-pharyngeal region; cartilaginous and non-collapsible laryngeal and tracheal regions. The fundamental dissimilarity between these two segments may result in an inherent collapsible tendency of the UA oro- pharyngeal region during sleep. Unlike the cartilaginous

component, the muscular segment of oropharynx is dependent on muscle tonus and head posture for patency, and this segment is controlled by central nervous system whereas the cartilaginous region is influenced by autonomous nervous system.

It has been affirmed that sleep influences certain changes in muscle tonus and activity such as 4: decrease in tonus during Non-rapid eyeball movement (NREM) stages II, III and IV of sleep; partial muscle paralysis during REM sleep stage due to the action of inhibitory neurotransmitter Glycine. During respiratory airflow a balance of forces must exist between dilatory forces of pharyngeal muscles and collapsible forces of primary respiratory muscles ⁵. This balance is lost during sleep as a result of reduced muscle tonus. It can be hypothesized that reduction in muscle tonus and loss of balance between forces can result in reduced UA dimensions during sleep, which may in turn act as a risk factor for reduced sleep efficiency due to respiratory effort related micro-arousals (MA) and sleep fragmentation (SF), a condition termed as Upper airway resistance (UAR), leading to Obstructive sleep apnea.

OSA can be categorized to three types (Mild/Moderate/Severe) based on their severity as indicated by the AHI index ⁶. Mild type of OSA is a more common

condition than Obstructive sleep apnea (OSA), with a high prevalence rate of one in every five individuals ¹. Mild OSA exhibits less severe clinical signs and manifestations and therefore diagnosis is more challenging. Dimensions of the UA (volume, surface area, antero-posterior and lateral width) is speculated to decrease during sleep, thereby acting as a risk factor for OSA resulting in reduced sleep efficiency, MA and SF. The above-mentioned speculation was analyzed and association between UA dimensions during sleep and reduced sleep efficiency was investigated by this 3-dimensional imaging study of the upper airway during sleep.

Degree and region specificity of UA obstruction is a critical factor in management of mild OSA. It is apparently evident from the observations by various researchers, as reported in the documented literature, that pharyngeal and soft palatal muscles play a critical part in UA dimensional changes during sleep ⁷⁻¹¹. Despite this logical substantiation, current modalities of management of mild OSA with oral appliances intend to prevent the UA obstruction by positioning the tongue in anterior relation and thereby preventing tongue fall back and airway obstruction. Mandibular Repositioning Splint (MRS), a commonly favored oral appliance therapy for mild OSA, does not approach or resolve

the obstructions at velo- pharyngeal/soft palate/naso-pharyngeal regions. And a long-term usage of MRS in OSA patients has been shown to cause unwarranted complications in the Stomato-gnathic system¹²⁻¹⁴.

Motivation and Problem Solving: OSA being a clinical entity with soaring incidence rate, wide age-group distribution, having diverse etiologic factors, showing multi-system involvement and broad manifestation, flings many challenges to a Clinician or Researcher. Familiarity of the Patho-physiology of OSA confirms the different possible zones/areas of upper airway obstruction leading to sleep disturbance. Henceforth it is imperative that OSA must be diagnosed and managed based on the zone of obstruction/constriction of upper airway in each individual case. Oral appliance modality for management of mild OSA and the efficacy of the treatment with oral appliances is completely dependent on the type of appliance chosen for a given case of OSA with specific zone of UA obstruction/constriction. The design and approach of the appliance must be based on the diagnosis of the type of OSA.

Based on these assertions, this research was planned with three major objectives:

1. To evaluate the UA by three-dimensional imaging technique and to compare between healthy subjects and mild OSA subjects. Such an evaluation will aid in – better understanding of the UA dimensional changes in mild OSA subject with relevance to different zones of constriction. It will also enable to categorize the mild OSA subjects into two broad categories – Retro-palatal and Retro-glossal zones of UA constriction. Percentage of occurrence/distribution of both types can be inferred. This technique of categorizing mild OSA subjects may possibly henceforth serve as a blueprint for diagnostic assessment and labeling of UA obstruction in OSA subjects, thereby aiding in choosing the type of treatment modality.
2. To plan, design and develop a new oral appliance modality for management of mild OSA subjects with Retro-palatal zone of constriction. To preliminarily evaluate and assess the treatment efficacy of the appliance through – subjective evaluation by patients“ inputs and also by reliable objective assessments.
3. To definitively evaluate and scrutinize the treatment efficacy of the new appliance modality through three-dimensional imaging analysis of upper

airway and also to compare the outcome with that of the existing oral appliance modality for management of mild OSA with Retro-glossal narrowing.

Each of these three objectives were carried over by designing a research protocol for each – hence three phased research was planned with the findings and inferences of each phase leading to the next phase of research.

First phase of the research was designed to compare the UA changes in mild OSA subjects and compare with healthy subjects through a three-dimensional imaging analysis. Findings of this phase of the study showed that there is definitive association between reduced UA dimensions and reduced sleep efficiency. It was also inferred from this phase of study that mild OSA with Retro-palatal zone of narrowing had a larger distribution among the samples (63.3%) thereby indicating that Retro-palatal zone of narrowing is significantly more common in mild OSA subjects than retro- glossal zone.

In the second phase of research a new appliance design, Naso-pharyngeal appliance (NPA), was developed, as stated elsewhere in a prior publication by the Principal Researcher ². This new appliance design was planned and proposed for

management by correcting the velopharyngeal/naso-pharyngeal/soft palate regions of UA obstruction. The efficacy of the new device was evaluated by clinical predictors, oral and nasal endoscopy analyses to reveal the better outcome with NPA than MRS by the author of this manuscript in preliminary research ².

The third phase of the study was designed to definitively evaluate the effectiveness of NPA in improving the airway volume and dimensions during sleep in mild OSA subjects and to compare with healthy subjects by 3d- imaging analysis of UA. Comparison of treatment outcomes with MRS and NPA was done by a randomized clinical trial with Independent Concurrent trial groups and Double-blind study design to attain relevant data.

This three-phase research aimed at categorizing the OSA subjects based on zone of obstruction and then developing a new appliance design for Retro-palatal zone of constriction. The new appliance NPA was developed by the Principal Researcher, with the intention of usage in patients with retro-palatal zone OSA, for which there is no existing oral appliance in use now.

Henceforth, this appliance was given only for the subjects with retro-palatal OSA. For the purpose of comparative analysis, it was

decided to compare the efficacy of NPA in treatment outcome with the conventional MRS. As we know MRS can be effective only in subjects with retro-glossal OSA, hence just for the purpose of studying the outcome and improvement in upper airway after appliance usage, it was decided to have two different groups - Retro-palatal and retro-glossal OSA subjects, NPA was given to subjects in retro-palatal group and MRS to subjects in retroglossal group.

On upper airway imaging analysis, the comparison between these groups and the healthy control group gave us a clear picture of the efficacy of both the appliances in the improvement of UA in respective groups. And NPA had a better efficiency in the sense that it improved the upper airway volume and measurements values, almost closer to the control group of healthy subjects.

This helped us in concluding that OSA must be categorized based on zone of obstruction and both the retro-glossal and retro-palatal types must be managed with different appliances. Our new appliance design is suitable for retro-palatal zone OSA. The new appliance also showed a good improvement in upper airway measurements, better than what the MRS could achieve.

Discussion of the relative merits of methods followed

Preliminary case sheets for sleep analysis (first case sheet - questionnaire), data collection forms (second case sheets), Diagnostic Overnight Polysomnography (DOP) were done to eliminate confounding factors and to adhere to stringent inclusion criteria. DOP was done for all the subjects as it is considered as reliable diagnostic tool for evaluation of sleep pattern ¹⁵. SFI was used for evaluating sleep efficiency and arousals since it is asserted as a practical and easy tool for sleep analysis ¹⁶.

Imaging was done when a subject was in NREM stage 2 of sleep as shown by Polysomnographic data and when subject was in supine position, as supine position is shown to increase the airway collapsibility than the lateral recumbent position ¹⁷ and head rotated supine position ¹⁸. NREM stage 2 of sleep was chosen with two justifications: partial muscle paralysis is a characteristic of REM sleep stage 4 thereby increasing the collapsible tendency of UA even in healthy individuals, thus making the differentiation between healthy and UARS subjects very difficult; NREM stage 2 of sleep accounts for 45%-50% of total sleep cycle 4 and has a significant role in UA obstruction related sleep disturbance, making it more relevant for this study.

BMI index range of 18.5 to 29.99, which is considered as the “Normal to Mild overweight” range 19, and age group of 25-35 years, which is considered as middle age group, were chosen as subject inclusion criteria for the research in order to minimize the influences of obesity and old age on upper airway and sleep. The subjects of control and sample groups were matched for Cephalometric variables (which denote their craniofacial skeletal architecture)²⁰⁻²². This will aid in minimizing the effect of these confounding factors on the outcome and inferences of the research.

The basic investigative procedure followed in this three-phase research was UA imaging and analysis of the dimensions. UA imaging study was used for confirmation of inclusion criteria for control and sample groups, for assessment of zones of UA obstruction in phase I of research and to definitively evaluate the treatment outcome with the new Nasopharyngeal appliance in phase III of the research. Hence at the beginning of this three-phase research, developing a reliable and repeatable technique of UA imaging and dimensional analysis was very much imperative. With this intention, the Principal researcher analyzed the different possible methods of UA imaging analysis stated in the literature.

Going through the documented scientific literature, it was affirmed that the methods commonly followed by clinicians and researchers for UA imaging analysis are – the older method of lateral cephalometric analysis, Computed Tomography (CT) imaging study, 3- dimensional CT imaging study, Magnetic Resonance Imaging (MRI) analysis and cine-MRI technique. The pros and cons of each technique were carefully considered while selection of the appropriate method for UA imaging analysis for this research.

The four basic points of contemplation in the research with regard to UA imaging analysis are

- 1) UA imaging has to be done in a three-dimensional manner so as to facilitate the precise measurement of dimensions and also to derive a more clinically and research oriented relevant data – UA volume. (Volume, being a three-dimensional measure, will give a more relevant inference by showing the exact dimensions and dynamic changes in UA before and after appliance wear by subject).
- 2) The UA dimensional analysis to be followed in this research has to be done when the subject is in a state of non-pharmacologically induced sleep, as discussed earlier, to obtain a more

clinically relevant data to compare between healthy and OSA subjects. 3). The UA imaging analysis must be reliable and repeatable without much of variation between observers and time dependant variation within observer. This reliability and repeatability are vital for testing the validity of this research if required and also for future researches with similar protocol. 4) Minimally invasive for the subject – as less radiation exposure and discomfort for the subject involved as possible.

Considering these points of deliberation, each of the imaging analysis was mulled over for appropriateness and suitability for this research. As a prelude, a comparative study was done with 30 subjects to analyze the preciseness of UA dimension measurement with lateral cephalometric analysis as mentioned in the testing methods followed in phase I of research. All the 30 subjects had clinical manifestations of OSA as confirmed by following the sequence of sampling methods mentioned earlier in “Research Protocol and Methodology” section. In an ideal clinical setting, diagnosis OSA by imaging techniques will depend on the clinician’s judgment in picking up the appropriate signs. To find this out we devised a novel system to compare the efficacy of lateral cephalometric analysis in

diagnosis of OSA as follows. Lateral cephalometric imaging was done after positioning the subject using a cephalostat in Kodak 8000C digital panoramic and cephalometric system. The lateral cephalometric films obtained from 30 subjects were given to 10 different senior practicing Orthodontists (observers), one person at a time. Each observer was requested to perform tracing of anatomical markers and measurements mentioned below for UA analysis.

Anatomic markers and lateral cephalometric measurements: ²³ (Fig. 4)

Hard tissue markers

Go – Gonion: Point marked at the junction of tangents drawn along lower border of mandible and distal border of ramus. It denotes the angle of mandible

B – Supramentale: Deepest hard tissue land mark on anterior mandible above the mental prominence

B-Go: Line connecting B and Go.

Soft tissue markers

Psp: Most superior-posterior point of soft palate

Tb: Dorsum of tongue on a line joining the Gonion and Supramentale (B-Go) Phw1: Posterior pharyngeal wall at the level of posterior superior airway space.

Phw2: Posterior pharyngeal wall at the level of inferior airway space.

Measurements in soft palate and oropharynx levels

- 1) **Phw1-Psp:** Superior posterior airway space (Distance measured along line parallel to B-Go)
- 2) **Phw2-Tb:** Inferior airway space between posterior pharyngeal wall and dorsum of tongue (Line parallel to B-Go)

From the cephalometric tracing and analysis, Phw1 and Phw2 denoted the UA dimension in superior and inferior levels. These values were arrived at for all 30 subjects through tracing and measurements on cephalometric films by all 10 observers separately, one at a time. The information of tracing by different observers was not shared between them to eliminate bias. All 10 different values were evaluated for consistencies and compared with the repeatability of UA analysis with 3-dimensional CT imaging and computer software program. We found that there was a wide inter- observer variability in the cephalometric analysis. On a closer look it was affirmed that this variability has occurred due to unevenness between observers in marking the soft tissue landmarks. From this it was affirmed that

lateral cephalometric method of UA assessment has a high degree of variability between observers since the analysis uses certain soft tissue markers.

Moreover, lateral cephalometric analysis gives only two-dimensional measurements, thereby it is apparent that by following this method, the observer may miss to identify certain significant changes in the UA dimensions which may not be evident in the two-dimensional measurements with lateral cephalometrics. Furthermore, it is logical that lateral cephalometric imaging can be done only when the subject is upright as in standing or sitting posture, thus rendering it impossible to do the imaging of UA when the subject is in sleep.

From these coherent contemplations, it is ascertained that lateral cephalometric analysis of UA dimensions has the following demerits – high degree of observer dependant variability (poor repeatability and reliability); 2-dimensinal measurements may not illustrate certain vital changes in UA shape and size; lack of applicability in UA imaging of subjects during sleep. Thus, it was decided that lateral cephalometric analysis of UA dimensions cannot be used in this three-phase research, although it is known to cause lesser radiation exposure for subjects than CT imaging. Also in the documented literature, it is stated that cephalometric

analysis is considered inadequate for assessing UA dimensions²⁴. CT imaging analysis has been affirmed to be useful in UA imaging and analysis²⁵. 3-dimensional CT imaging and computerized analysis methods have been recently used for UA imaging and dimensional evaluation in OSA subjects with affirmative results²⁶⁻²⁹ justifying the choice of 3d CT imaging and computer software analysis as methodology for the current study.

MRI analysis, as recognized, has certain significant advantages as – no radiation exposure for subjects and precise imaging of soft tissue markers for 3- dimensional analysis of UA. Despite of these advantages, there was a practical difficulty in following MRI analysis in this research, as ascertained during the trial method of using MRI analysis for few subjects in earlier stage of devising the research protocol for the research. It was observed during this trial that the MRI machine produced significant noise during its operation that it was impossible for the subject to sustain the state of non-pharmacologically induced sleep, which was required as a protocol for this research.

In consequence of the above deliberations, it was decided that 3-dimensional CT imaging and computer software analysis can be the most appropriate method to study the UA dimensions in this three phase

research. Following the 3-dimensional CT imaging, 3-d reconstruction physical model of UA was done for a few subjects by rapid prototyping technique (Fig. 8 & 9). But this 3-d reconstruction physical model did not provide any significant changes in dimensional measurements form those obtained from the software analysis of CT images. Hence this physical model method was not followed in the further stages of this three phase research.

Statistical analysis and interpretation of the data from phase 3 of research revealed that subjects in Group A (control) exhibit significantly higher values of airway patency, volume, a-p width, lateral width and area in Retroglossal and Retropalatal regions than Group B and C subjects (Fig. 17); Subjects in Group C showed better improvement in the airway dimensions after NPA placement than subjects in group B after MRS placement (Fig. 18).

From these findings, conclusions were derived for the sample: there is definite association between reduced UA dimensions and reduced sleep efficiency, increased MA and SF; NPA can give better treatment outcome for mild OSA with Retro-palatal zone of narrowing by improving the UA dimensions. The null hypothesis was rejected based on these verdicts. Generalizing these conclusions from sample to the population was done

with adequacy, since probability sampling method by random assignment was followed during subject inclusion criteria for the research.

CONCLUSIONS:

This research was planned and carried out with the objective of improvising and broadening the scope of management of OSA with relevance to “Case-Effect Management” principle. From the documented literature, it is undoubtedly evident that OSA is a clinical entity that flings various challenges to a clinician/researcher such as high incidence rate, wide age-group distribution, diverse etiologic factors, multi-system involvement and broad manifestation. Thorough knowledge of Pathophysiology of OSA leads us to an understanding that different possible zones of Upper airway constriction in OSA subjects must be thoroughly studied.

Hence first phase of the research was designed with this same intention of studying the UA changes and zones of narrowing in mild OSA subjects in comparison with healthy individuals through a three-dimensional imaging analysis.

Findings from the first phase of the research resulted in these four basic inferences and conundrums –

- 1). Diagnosis of OSA must be more relevantly based on the zone of Upper airway (UA) narrowing, and not just based on the severity of symptoms as commonly perceived through the current literature.
- 2). Such an understanding of the relevance of the zone of UA narrowing will aid us in categorizing the OSA subjects in to two broad types – Retro-palatal and Retro-glossal zones of narrowing.
- 3). Studying the percentage of distribution of both the types in OSA in the population is very imperative. Retro-palatal zone of narrowing is found to be more prevalent.
- 4) Treatment approach must be different for both types – Retro-glossal zone of UA narrowing can be managed by the currently existing and commonly followed types of oral appliance modalities
 - Mandibular repositioning / Tongue retaining appliances. Retro-palatal zone of constriction requires a new type of appliance to be designed as there is currently no modality of oral appliance that engages and corrects retro-palatal narrowing of UA in OSA subjects.

The first phase of research also served as a medium to develop, set-right and establish a reliable technique for three-dimensional imaging analysis of UA, so that such a technique can be used in a „dry-run“ manner during this phase I before using it

as a more definitive, precise method for further subsequent research phases.

Based on the inferences and conundrums that cropped up through the findings of first phase of research, second phase of research was planned with the target of developing a new appliance design for management of mild OSA with Retro-palatal narrowing and also to preliminarily evaluate and assess the efficacy of the new appliance design in management of OSA. The findings of the preliminary evaluation of efficacy through the phase II of research were very encouraging as inferred from a series of both subjective and objective analyses. Third phase of research was designed to definitively evaluate the treatment outcome and efficacy of the new appliance design – Naso-pharyngeal appliance (NPA) in management of mild OSA with Retro-palatal zone of UA narrowing. This definitive evaluation was a three- dimensional image analysis of the UA dimensions and assessment of improvement after the appliance wear. It is affirmed based on the third phase of research that management of mild OSA with Retro-palatal zone of narrowing using the new appliance design, Naso-pharyngeal appliance (NPA) resulted in significant improvement of UA dimensions after appliance wear. **Inferences from Phase I of research:** 1) Adult subjects with

susceptibility of reduction in UA volume and dimension during sleep will exhibit sleep fragmentation, micro-arousals and reduced sleep efficiency in comparison to subjects without reduction in UA dimensions in sleep. 2) UA dimensions (Airway patency, Antero-posterior width, Lateral width, Surface area and Volume) are significantly reduced in subjects with mild OSA than healthy subjects

- 3) Mild OSA with Retro-palatal zone of narrowing had a larger distribution among the samples (63.3%) thereby indicating that Retro-palatal zone of narrowing is significantly more common in mild OSA subjects than retro-glossal zone.

Inference from Phase II of research: the newly designed appliance – Naso-pharyngeal appliance (NPA) showed a better outcome in all parameters of assessment in both subjective and objective evaluations

Inference from Phase III of research: The null hypothesis stated in the research design is rejected for the sample based on the inferences from the data. NPA resulted in better improvement of UA dimensions during sleep in subjects with mild OSA with Retro-palatal narrowing than MRS in

mild OSA subjects with Retro-glossal narrowing. Generalizing the inferences of the research from sample to the population, the following inference is derived

- 1) Management of mild OSA with retro-palatal zone of narrowing with NPA

resulted in desired outcome of improvement in UA dimensions (Airway patency, Anteroposterior width, Lateral width, Surface area and Volume) during sleep.

REFERENCES:

1. Waldhorn RE. Sleep apnea syndrome. Am Fam Physician 1985; 32:149.
2. Venkat R, Gopichander N, Vasantakumar M. Four novel prosthodontic methods for managing upper airway resistance syndrome: An investigative analysis revealing the efficacy of the new nasopharyngeal aperture guard appliance. Indian J Dent Res 2010; 21:44-48.
3. Puhon M A et al., Didgeridoo playing as alternative treatment for Obstructive sleep apnea syndrome: randomized controlled trial. Brit Med J 2006; 332(7536):266- 70.
4. Moorcroft WH. Understanding Sleep and Dreaming. Chapter 1: What is sleep and how is it scientifically measured"; Chapter 4: The brain in sleep". Springer Science Spring Street, New York, USA: 2005; pg.25, 83-85.
5. Hudgel DW. Mechanisms of obstructive sleep apnea. Chest 1992; 101;541-49.
6. WT McNicholas. Diagnosis of Obstructive Sleep Apnea in Adults. Proc Am Thorac Soc 2008; 5:154–160.
7. Schwab RJ et al., Dynamic imaging of the upper airway during respiration in normal subjects. J Appl Physiol 1993; 74:1504-1514.
8. Isono S et al. Anatomy of pharynx in patients with obstructive sleep apnea and in normal subjects. J Appl Physiol 1997; 82: 1319–1326.
9. Ryan CM. and Bradley TD. Pathogenesis of obstructive sleep apnea. J Appl Physiol 2005; 99:2440-2450.
10. Shigeta Y. Soft palate length and upper airway relationship in OSA and non-OSA subjects. Sleep Breath 2010; 14:353–358.
11. Hudgel, DW and Hendricks C. Palate and hypopharynx site of inspiratory narrowing of the upper airway during sleep. Am Rev Respir Dis 1988; 138(6):1542- 154.
12. Almeida FR, Lowe AA, Sung JO, Tsuiki S and Otsuka R. Long-term sequellae of oral appliance therapy in obstructive sleep apnea patients: Part 1 Cephalometric analysis. Am. J. Orthod Dentofacial Orthop 2006; 129:195-204.

13. Chen H, Lowe AA, de Almeida FR, Fleetham JA and Wang B. Threedimensional computer-assisted study model analysis of long-term oral appliance wear. Part 2. Side effects of oral appliances in obstructive sleep apnea patients. *Am J Orthod Dentofacial Orthop* 2008; 134:408-417.
14. Inoko Y and Morita O. Influence of oral appliances on cranio-cervical posture in obstructive sleep apnea–hypopnea syndrome patients. *J Prosthodont Res* 2009; 53:107– 110.
15. Kushida CA, Littner MR, Morgenthaler T, Alessi CA, Bailey D, Coleman J Jr, Friedman L, Hirshkowitz M, Kapen S, Kramer M, Lee-Chiong T, Loubé DL, Owens J, Pancer JP, Wise M. Practice parameters for the indications for 148 polysomnography and related procedures: an update for 2005. *Sleep* 2005; 28:499- 521.
16. Haba-Rubio J, Ibanez V and Sforza E. An alternative measure of sleep fragmentation in clinical practice: the sleep fragmentation index. *Sleep Med* 2004; 5:577–81.
17. Walsh JH, Leigh MS, Paduch A, Maddison KJ, Armstrong JJ, Sampson DD, Hillman DR, Eastwood PR. Effect of body posture on pharyngeal shape and size in adults with and without obstructive sleep apnea. *Sleep* 2008; 31:1543-49.
18. Ono T, Otsuka R, Kuroda T, Honda E and Sasaki T. Effects of Head and Body Position on Two- and Three-dimensional Configurations of the Upper Airway. *J Dent Res* 2000; 79:1879-84.
19. Global data base on Body-Mass Index, W.H.O., 2004. Online source <http://apps.who.int/bmi/index> . (Accessed on 25/8/2010).
20. Vanessa GS et al. Correlation between cephalometric data and severity of sleep apnea. *Braz J Otorhinolaryngol* 2014; 80(3):191-95.
21. Ming FW, Takero O, Susumu A and Sadao S. Vertical facial height and its correlation with facial width and depth -Three dimensional cone-beam computed tomography evaluation based on dry skulls. *J Stomat Occ Med* 2013; 6:120–129.
22. Fariborz A, Ali BF, Gilda BR, Alireza J and Fatemeh S. Assessment of the uvulo-glossopharyngeal dimensions in patients with β -thalassemia major. *Sleep Breath* 2013; 17(3): 943-949.
23. Nonglak P, Mark GH, Kingman PS and Susan R. Upright and supine cephalometric evaluation of Obstructive sleep apnea syndrome and snoring. *Angle Orthod* 1994; 64(1):63-74.
24. Vig PS, and Hall DJ. The inadequacy of cephalometric radiographs for airway assessment - Letter to Editor. *Am J Orthod* 1980; 77: 230-32.
25. Caballero P, Alvarez-Sala R, García-Río F, Prados C, Hernán MA, Villamor J and Alvarez-Sala JL. CT in the Evaluation of the Upper Airway in healthy subjects and in patients with Obstructive sleep apnea syndrome. *Chest* 1998; 113:111-16.
26. Shigeta Y, Ogawa T, Ando E, Clark GT and Enciso R. Influence of tongue/mandible volume ratio on oropharyngeal airway in Japanese

- male patients with obstructive sleep apnea. Oral Surg Oral Med Oral Pathol Oral Radiol Endod 2011; 111:239-43.
27. Enciso R, Nguyen M, Shigeta Y, Ogawa T and Clark GT. Comparison of conebeam CT parameters and sleep questionnaires in sleep apnea patients and control subjects. Oral Surg Oral Med Oral Pathol Oral Radiol Endod 2010; 109:285-93.
28. Shigeta Y, Enciso R, Ogawa T, Ikawa T and Clark GT. Cervical CT derived neck fat tissue distribution differences in Japanese males and females and its effect on Retroglossal and retropalatal airway volume. Oral Surg Oral Med Oral Pathol Oral Radiol Endod 2008; 106:275-84.
29. Kaur A, Chand P, Singh RD et al. Computed tomographic evaluation of the effects of mandibular advancement devices on pharyngeal dimension changes in patients with obstructive sleep apnea. Int J Prosthodont. 2012; 25(5):497-505.

TABLES:

[In annexure](#)